



Femme de 76 ans

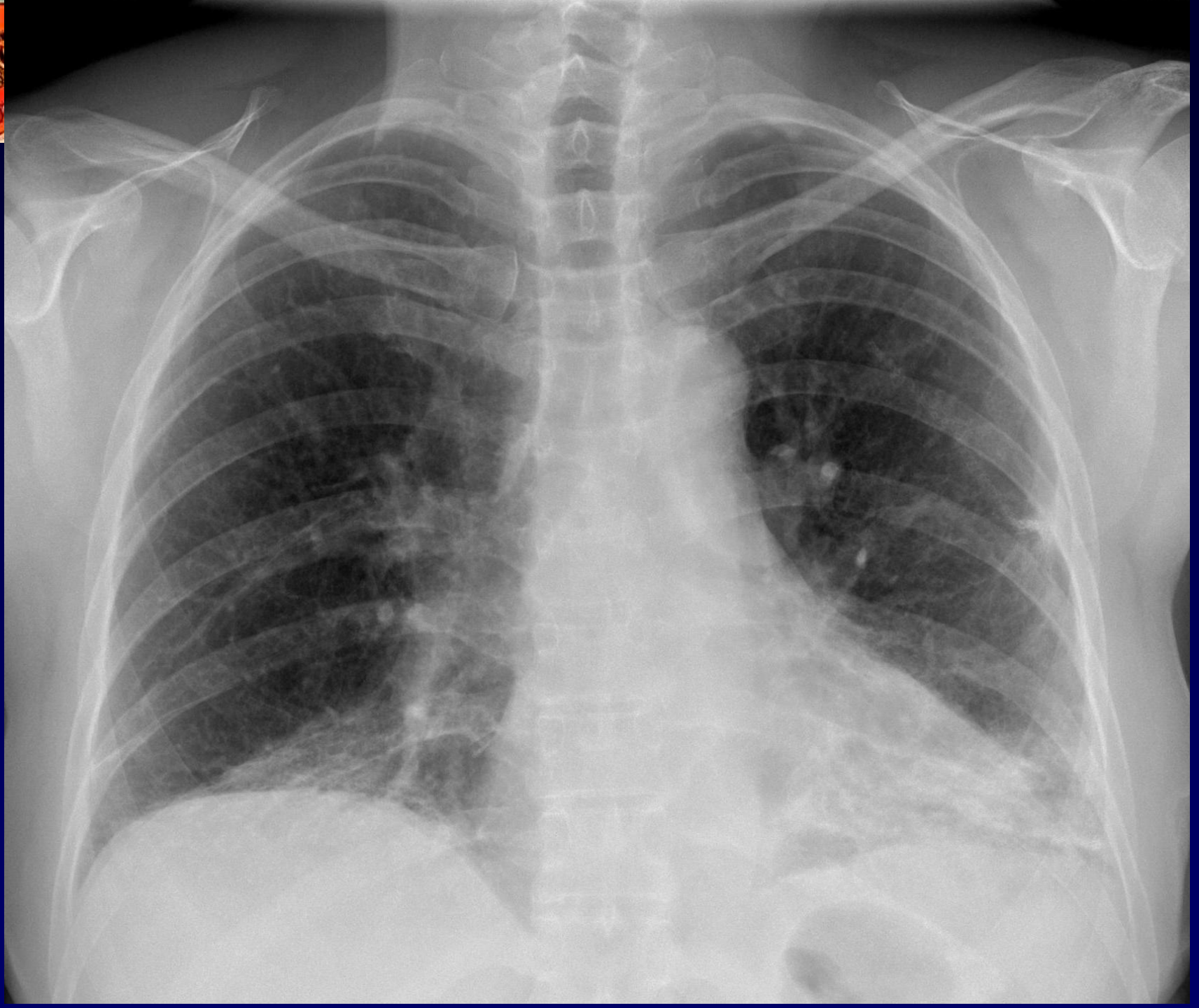
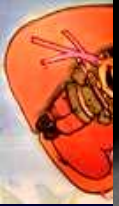Dyspnée Stade III NYHA

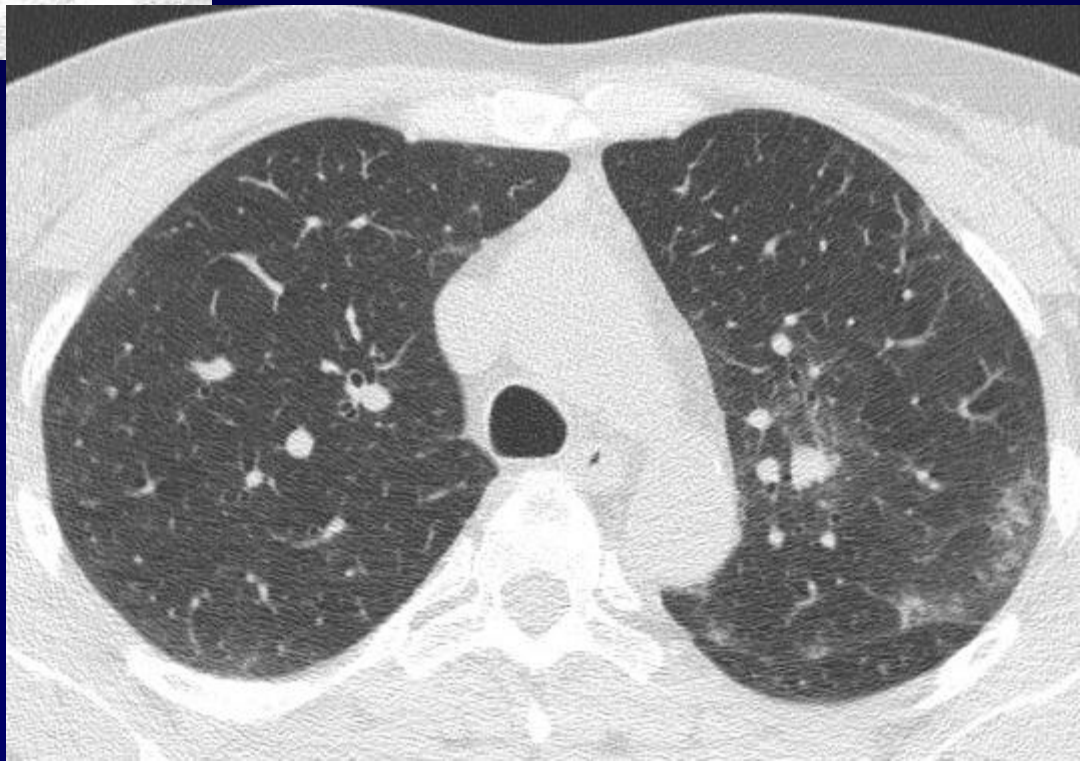
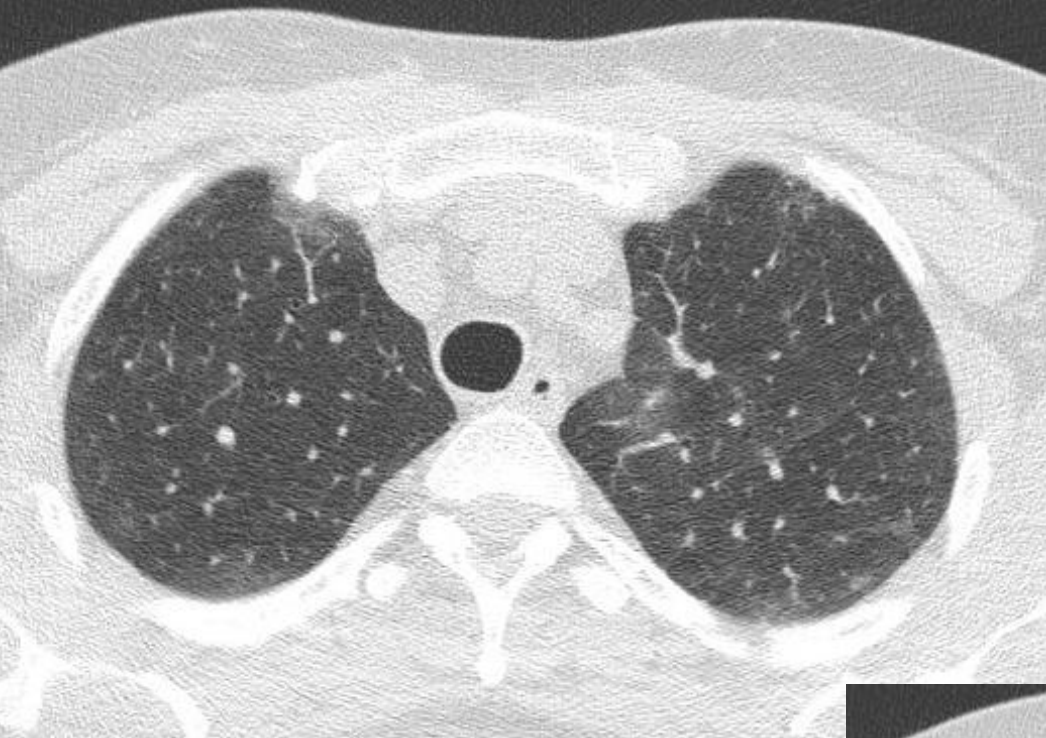Toux surtout à l'effort

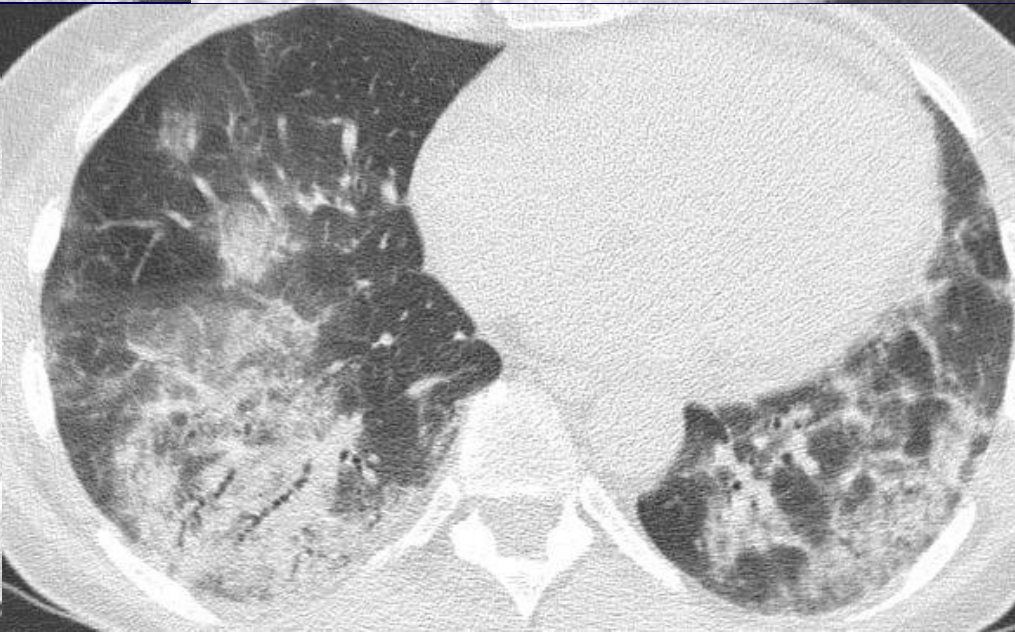
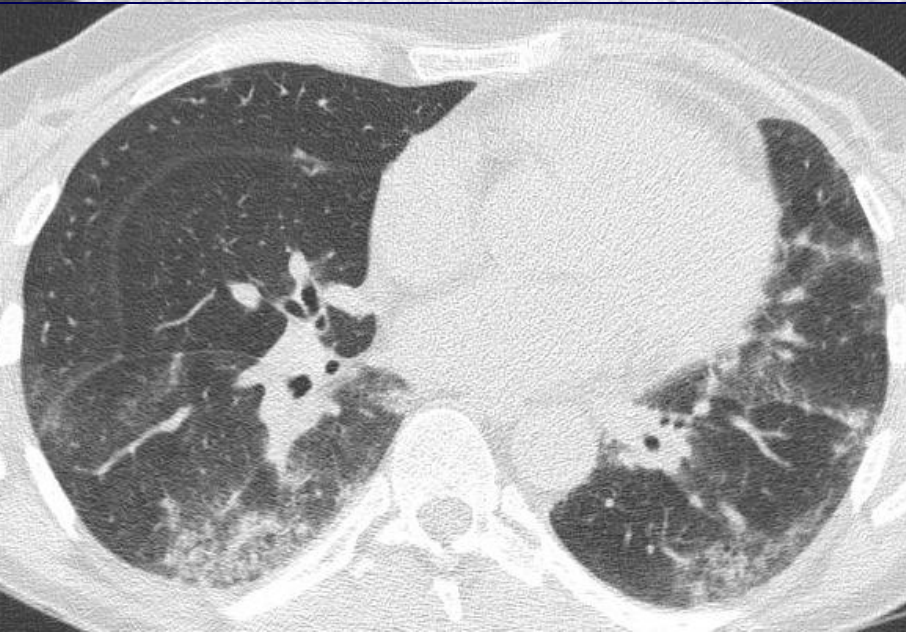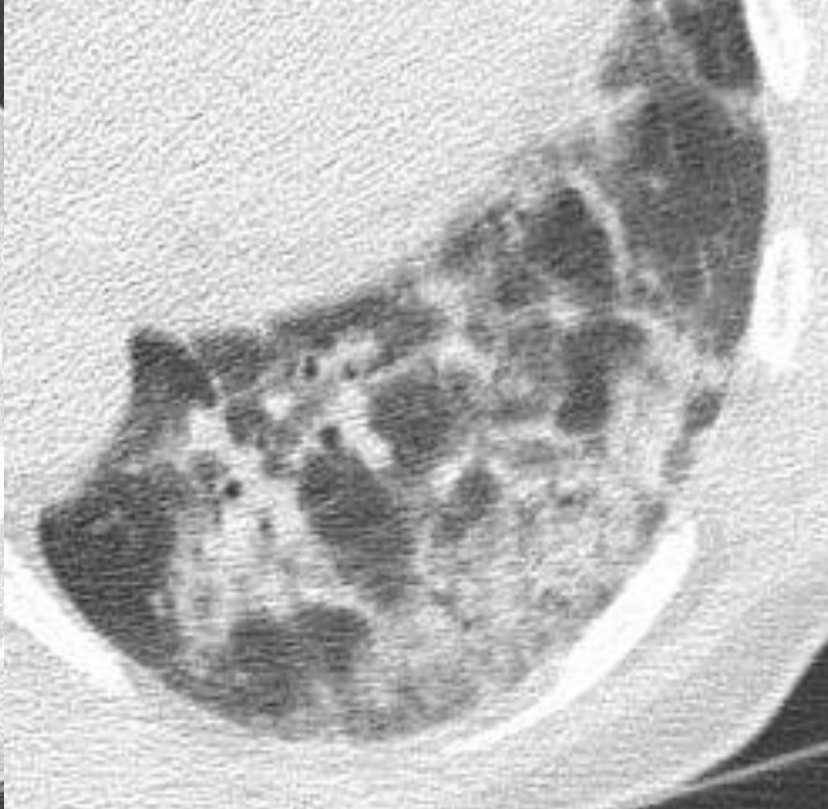
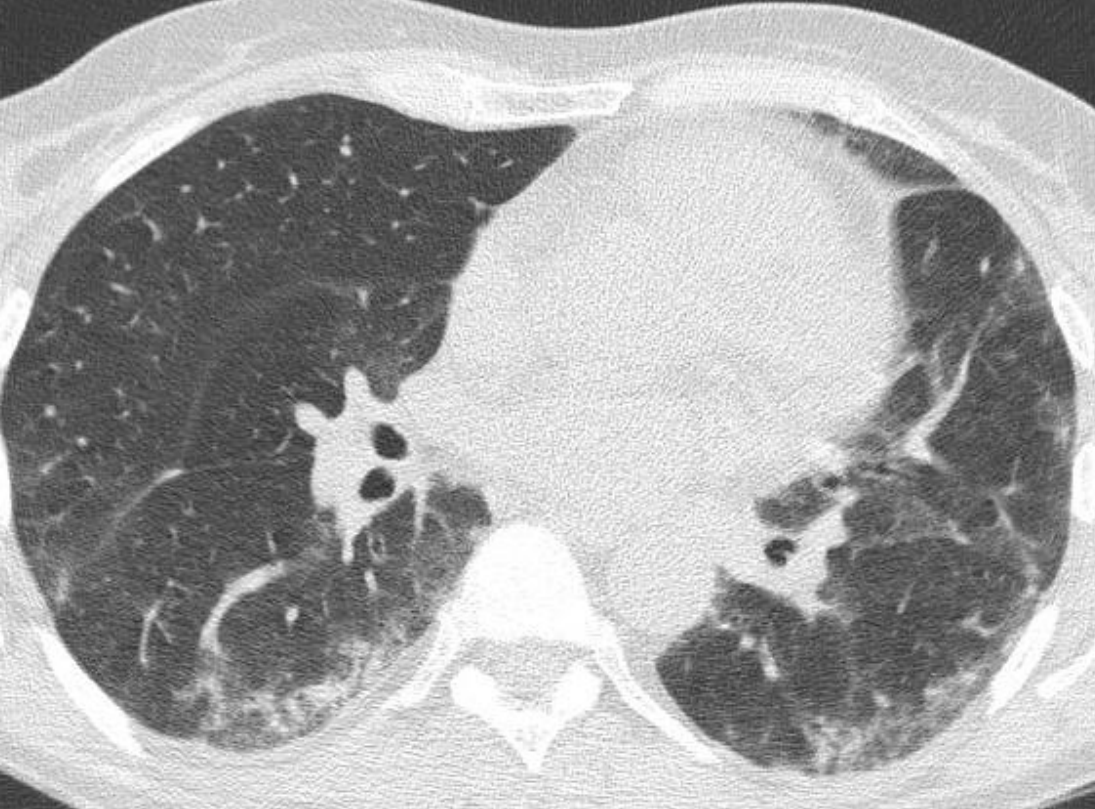
RGO -, Maladie systémique -, pigeons +

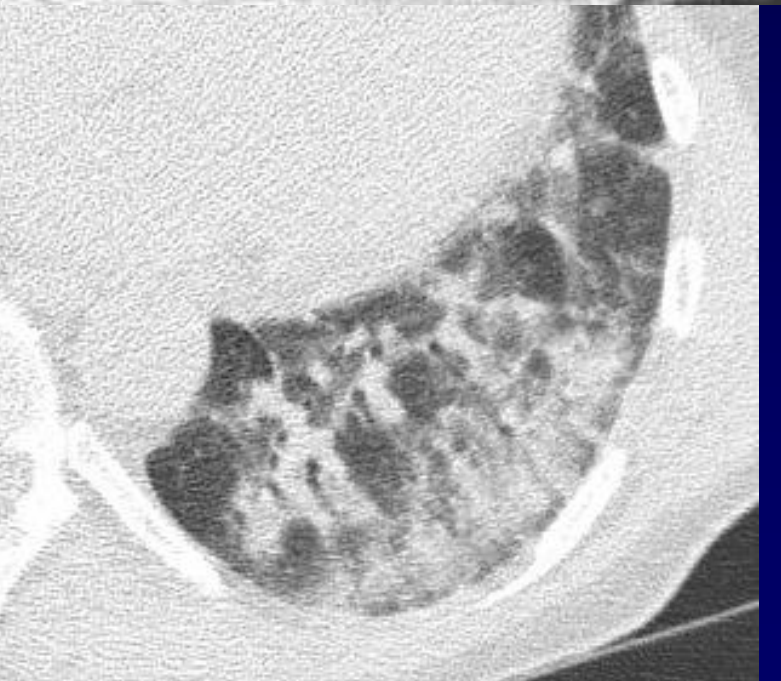
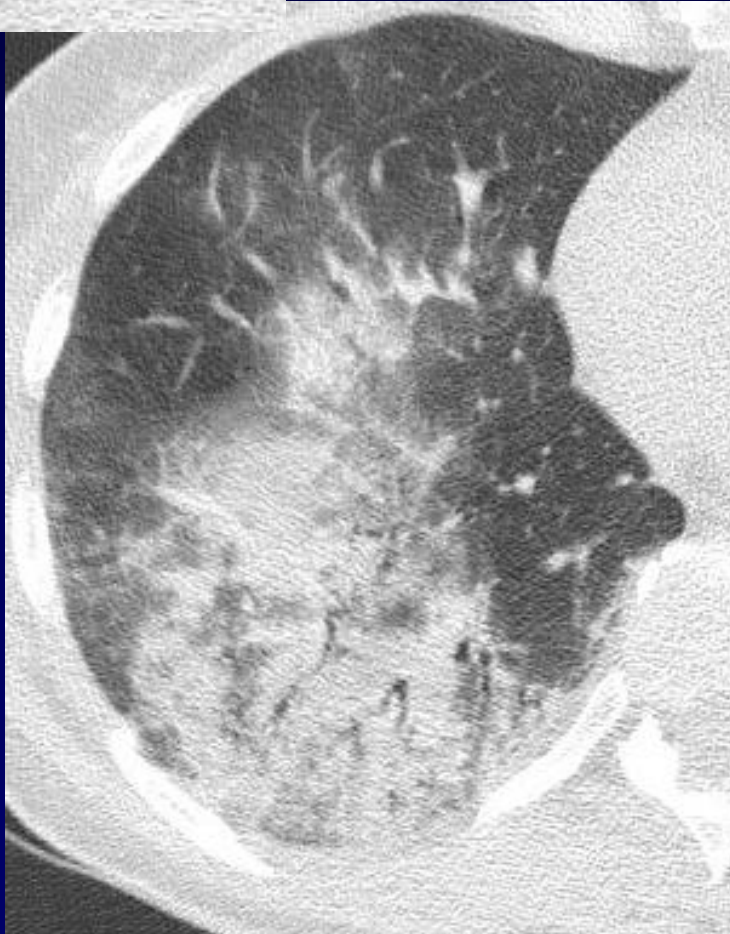
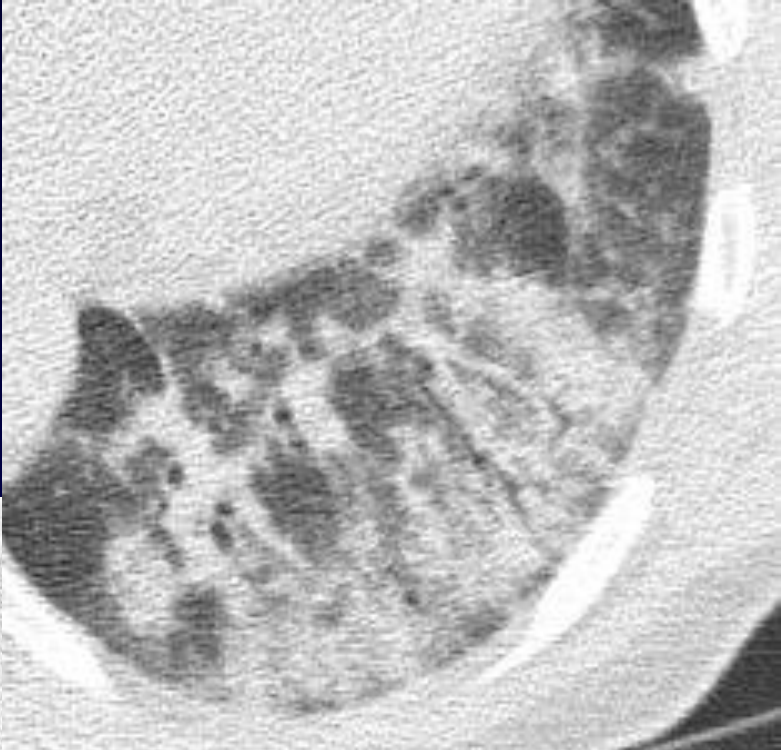
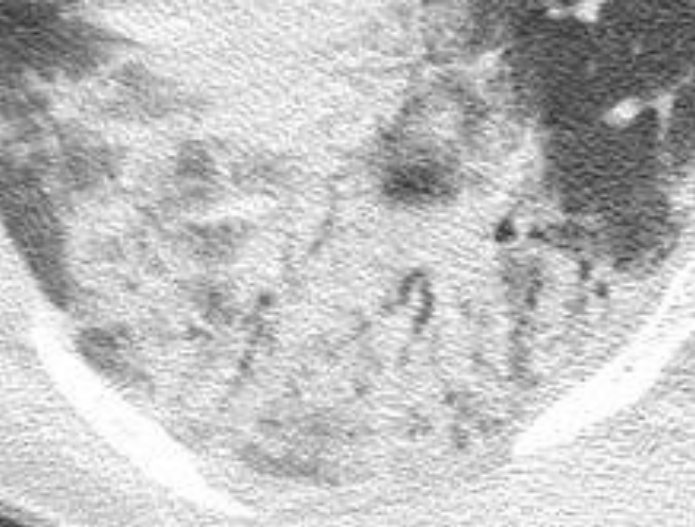
Examen clinique subnormal, crépitants des bases

EFR: Sd restrictif ( CPT 73%, VEMS 67%,  
Tiffeneau 84%) DLCO 59%



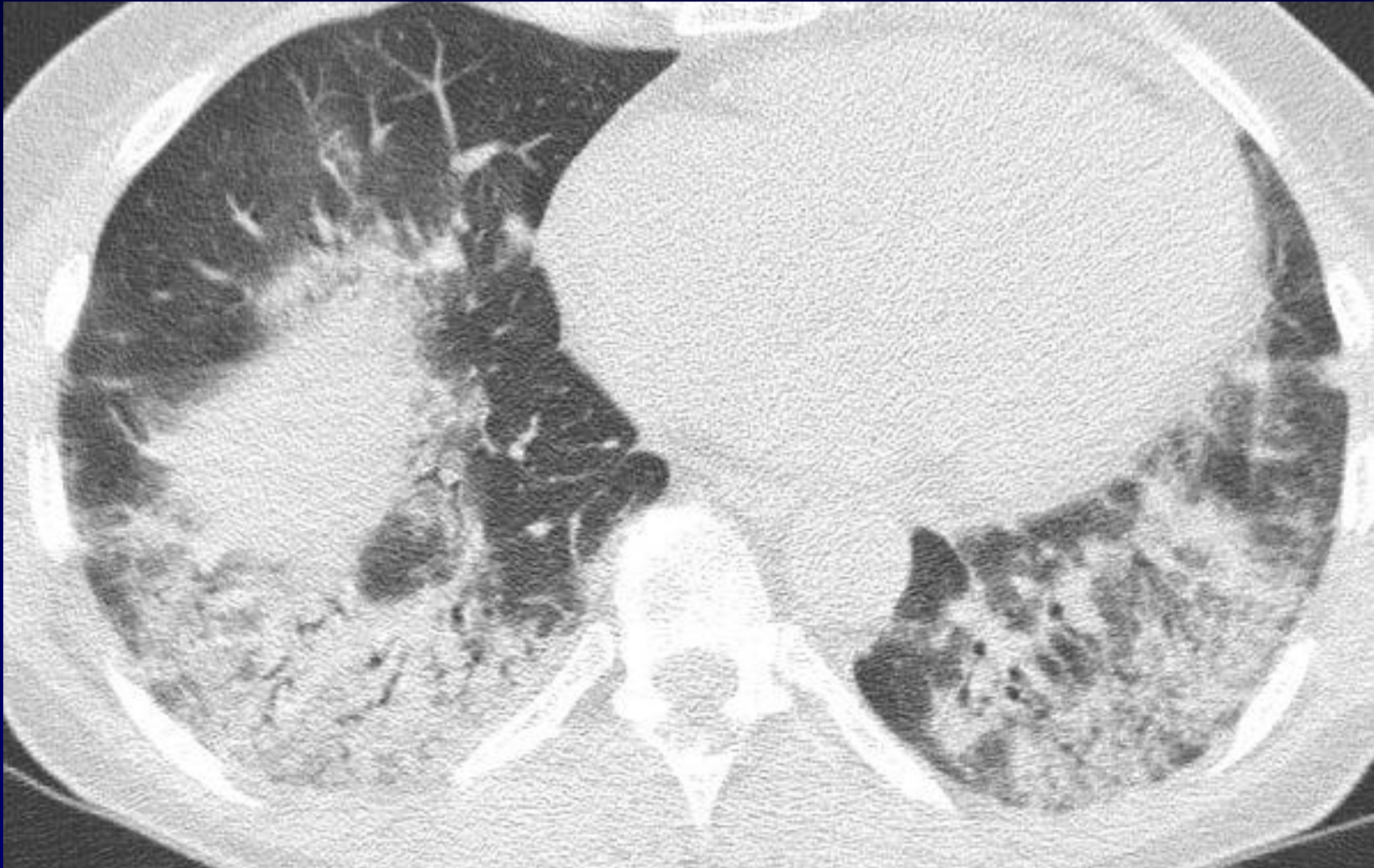


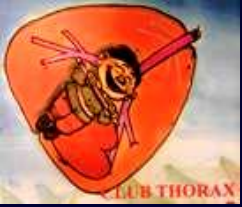




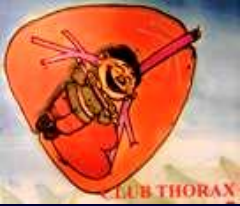# Diagnostic ?





## **Diagnostic**

**NSIP – COP associée à  
un syndrome de Gougerot – Sjogren**



- Amélioration de la clinique – EFR sous Corticothérapie 1 mg/ kg / jr
- Sjogren et poumon: SGS Secondaire >>  
SGSP
- PINS
- UIP
- LIP
- Bronchiolite folliculaire
- COP
- MALT

*Ito J - Am J Resp Crit Care Med 2005; 171: 632*